

PATIENT

Sprinkles King

PRESENTING CLINICAL SIGNS

P presented for US due to Vomiting and Diarrhea and decreased appetite for about 2 weeks. Bloodwork unremarkable, T4 wnl

SPECIES

Feline

ULTRASONOGRAPHIC EXAMINATION OF THE ABDOMEN

Urinary System

BREED

DSH

Full urinary bladder with a normal thickness and smooth appearance of the wall. Normal anechoic urine with no sediment or uroliths evident.

SEX

FS

Normal appearance of the trigone area, proximal urethra, and iliac blood vessels.

AGE

7yr

Normal appearance and size of the iliac lymph nodes. Ureters not visualized, which can be considered a normal finding.

Normal renal size, architecture, echogenic appearance, cortico-medullary differentiation, which maintains a 1:3 cortex to medulla ratio, pelvis, and capsule. No infarcts, mineralization or renoliths evident.

The left kidney measured 3.7 cm in length.

The right kidney measured 4.2 cm in length.

WEIGHT

12.5lb

Reproductive system NA.

Adrenal Glands

Normal shape, echogenic appearance, size, position, and appearance of the visible peri-renal vasculature.

The left adrenal gland measured 0.96 cm x 0.35 cm x 0.38 cm.

The right adrenal gland measured 0.85 cm x 0.37 cm x 0.38 cm.

INTERPRETED BY

Remo Lobetti, BVSc,
 MMedVet (Med), PhD,
 Dipl. ECVIM

Spleen

Normal size and echogenic appearance. Smooth homogenous parenchyma and regular curvilinear capsule. Normal volume of the splenic vasculature without any overt congestion or thrombosis evident. No inflammatory, neoplastic, infarction, or infiltrative changes evident. The spleen measured 0.7 cm in width.

IMAGING PERFORMED BY

Kathleen Byrnes

HOSPITAL NAME

Monroe Road Animal Hospital

Liver

Normal size, echogenic appearance, portal markings, and regular curvilinear capsule. No nodules or masses evident. Normal appearance of the hepatic and portal vasculature.

REFERRING VET

Dr Breckie

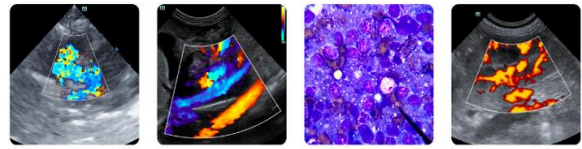
Gallbladder

Full containing normal anechoic bile. Normal thickness and echogenic appearance of the wall. Normal size and appearance of the cystic and common bile duct.

INVOICE
 25019

Gastrointestinal

DATE
 06/05/2026



PATIENT

Sprinkles King

Normal appearance of the stomach, duodenum, small intestine, ileo-cecal junction, and colon with no loss of layering, 1:3 muscularis to mucosa ratio, normal wall thickness and peristaltic activity, and no distension of the lumen.

SPECIES

Feline

Pancreas

Left lobe: normal size and echogenic appearance. Regular capsule. Normal echogenic appearance of the mesentery and fat surrounding the pancreas.

Right lobe: normal size with a hypoechogenic appearance but maintaining a regular curvilinear capsule. Normal echogenic appearance of the mesentery and fat surrounding the pancreas.

BREED

DSH

Free Abdomen

SEX

FS

Prominent gastric lymph node measuring ~ 0.4 cm in size with a rounded shape and hypoechogenic appearance. Rest of the mesenteric lymph nodes are of normal size and appearance.

No ascites evident.

AGE

7yr

ULTRASONOGRAPHIC FINDINGS

- Gastric lymphadenomegaly
- Pancreatitis?

INTERPRETATION OF THE FINDINGS & FURTHER RECOMMENDATIONS

The most likely etiology for the gastric lymphadenomegaly would be reactive hyperplasia. Further assessment would be FPL/PSL assay. Specific therapy would depend on an etiological diagnosis. Symptomatic management that could be considered would be feeding small frequent meals of a low-fat intestinal type diet, anti-emetics and intestinal absorbents/ protectants.

WEIGHT

12.5lb

INTERPRETED BY

Remo Lobetti, BVSc,
MMedVet (Med), PhD,
Dipl. ECVIM

**IMAGING
PERFORMED BY**

Kathleen Byrnes

HOSPITAL NAME

Monroe Road Animal
Hospital

REFERRING VET

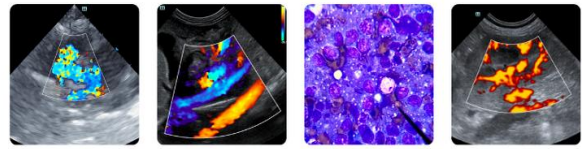
Dr Breckie

INVOICE

25019

DATE

06/05/2026



PATIENT

Sprinkles King

SPECIES

Feline

BREED

DSH

SEX

FS

AGE

7yr

WEIGHT

12.5lb

INTERPRETED BY

Remo Lobetti, BVSc,
 MMedVet (Med), PhD,
 Dipl. ECVIM

IMAGING PERFORMED BY

Kathleen Byrnes

HOSPITAL NAME

Monroe Road Animal
 Hospital

REFERRING VET

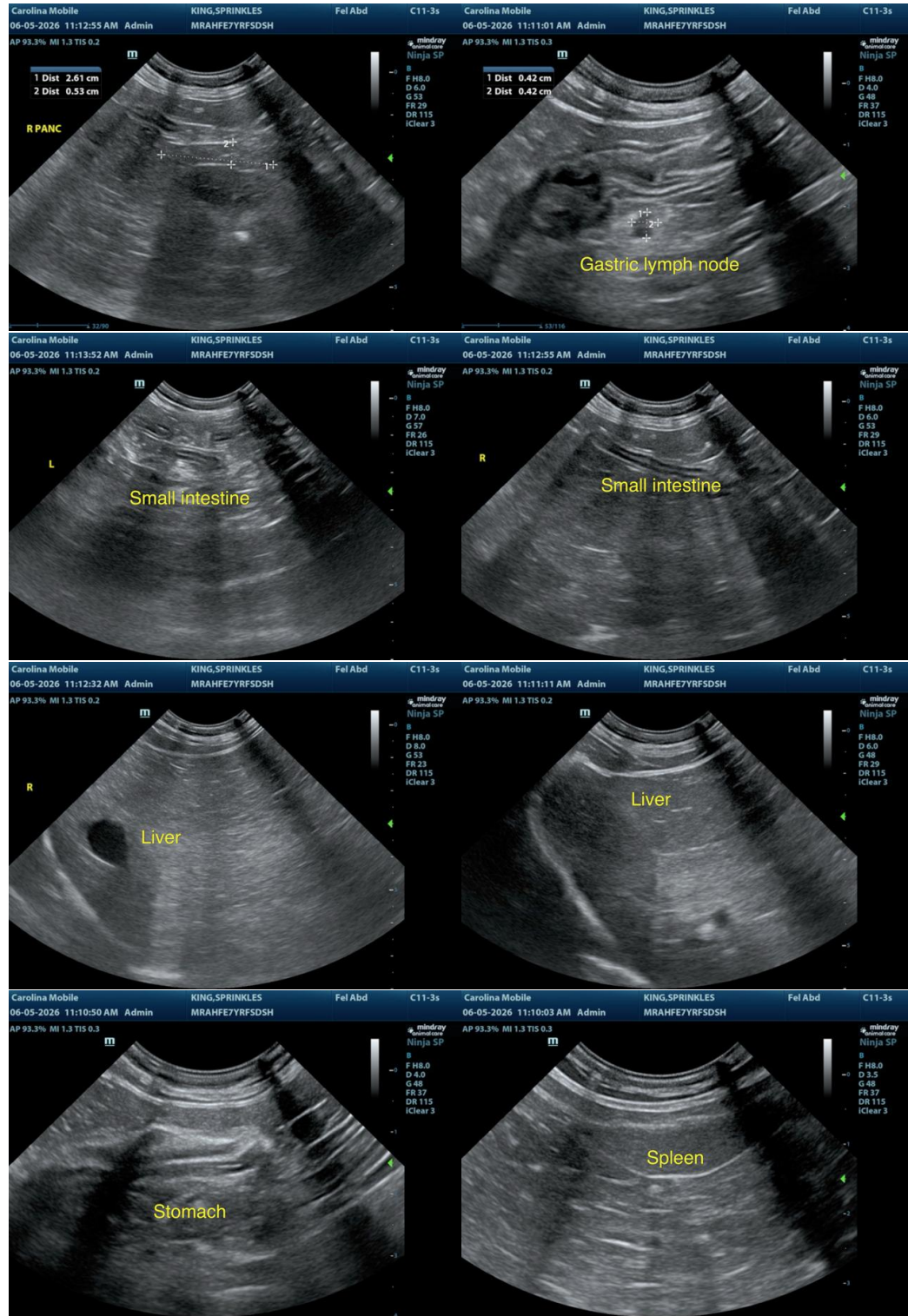
Dr Breckie

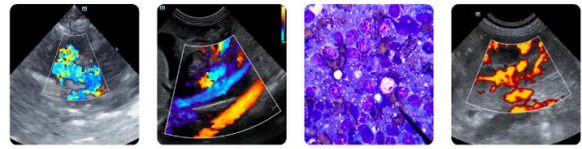
INVOICE

25019

DATE

06/05/2026





PATIENT

Sprinkles King

SPECIES

Feline

BREED

DSH

SEX

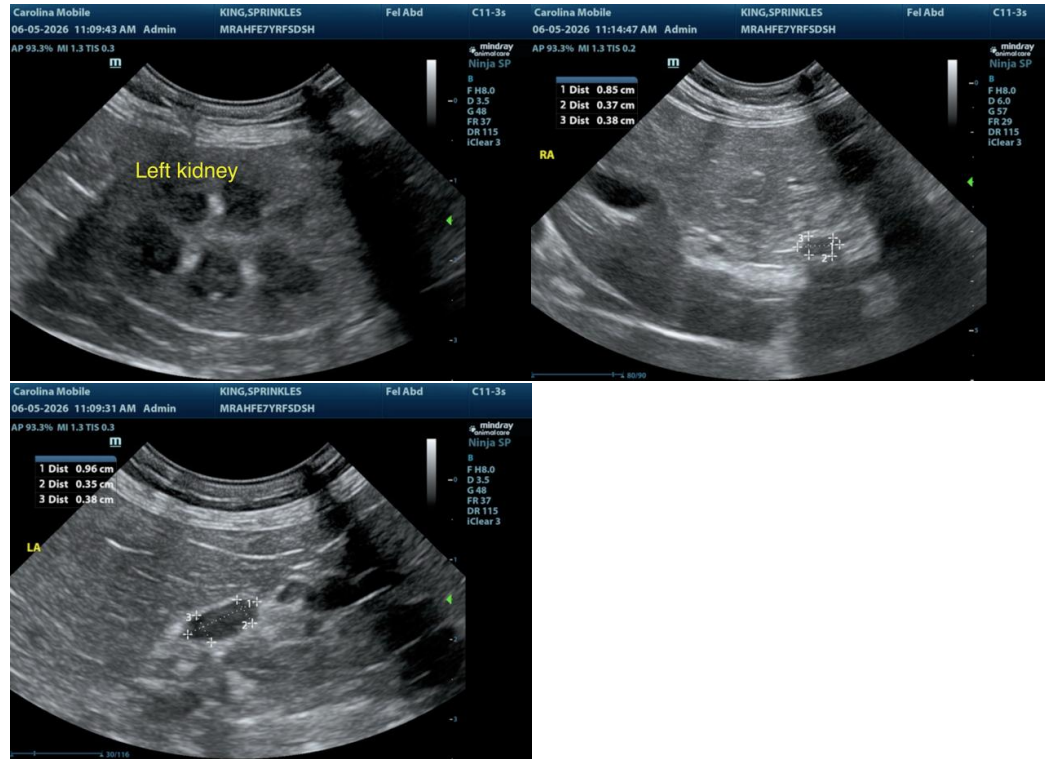
FS

AGE

7yr

WEIGHT

12.5lb



INTERPRETED BY

Remo Lobetti, BVSc, MMedVet (Med), PhD, Dipl. ECVIM

IMAGING PERFORMED BY

Kathleen Byrnes

HOSPITAL NAME

Monroe Road Animal Hospital

REFERRING VET

Dr Breckie

INVOICE

25019

DATE

06/05/2026

The information and recommendations provided are based on the images presented by the referring veterinarian. No evaluation can be communicated regarding pathology that was not visible in the image/video clips provided.

Thank you for this referral. If the clinical or image interpretation does not parallel your findings or if I can be of any further assistance, please contact me.

Remo Lobetti, BVSc, MMedVet (Med), PhD, Dipl. ECVIM (Internal Medicine)

info@sonopath.com